

Evaluating the Protective Effects of Aqueous and Hydroalcoholic Extracts of *Plantago Major* Leaf in a Rat Model of Ethanol-induced Peptic Ulcer

Bakhan Bahadeen Aref¹, Sajad Fakhri², Mohammad Reza Morovati³, Maryam Ghanbari-Movahed², Ehsan Mohammadi Noori², Shahram Miraghaei⁴ and Mohammad Hosein Farzaei^{2*}

¹Student Research Committee, Kermanshah University of Medical Science, Kermanshah, Iran

²Pharmaceutical Sciences Research Center, Health Institute, Kermanshah University of Medical Science, Kermanshah, Iran

³Persian Medicine Department, Faculty of Medicine, Kermanshah University of Medical Sciences, Kermanshah 6714869914, Iran

⁴Medical Biology Research Center, Health Technology Institute, Kermanshah University of Medical Science, Kermanshah, Iran

Article History: Received: 26 April 2022/Accepted in revised form: 16 August 2023

© 2012 Iranian Society of Medicinal Plants. All rights reserved

ABSTRACT

There is usually a connection between the secretion of stomach acid and stomach ulcers, but today the main cause of these ulcers is considered to be the presence and proliferation of *Helicobacter pylori* bacteria, which causes peptic ulcers in various ways, including damage to the protective layer. Therefore, the aim of this study is to investigate the protective effect of the aqueous and hydroalcoholic extracts of *Plantago major* leaves on gastric ulcers induced by ethanol in rats. First, 36 adult male Wistar rats were selected and divided into 9 groups including famotidine and control groups, healthy groups, and protective groups that received the aqueous and hydroalcoholic extracts of the leaves of the *Plantago major*. After preparing and checking the obtained results, quantitative data was evaluated with a one-way analysis of variance and Tukey's post hoc test using SPSS software. The macroscopic examination results showed that in both groups receiving aqueous and hydroalcoholic extracts of the *Plantago major* plant, the group receiving the extract with a dose of 200 mg/kg had the best protective effect compared to the control group. The general results of the present study showed that in both groups receiving the aqueous and hydroalcoholic extracts of the plant leaves, the group receiving the extract with a dose of 200 mg/kg had the best protective effect compared to the control group. In conclusion, our findings indicated that this extract is a potential agent that can be used for the treatment of peptic ulcers and gastric tissue wounds.

Keywords: Ethanol, Hydroalcoholic extracts, *Plantago major*, Peptic ulcer.

INTRODUCTION

Ulcers of the digestive system, especially the stomach, can be caused by increased acid secretion for various reasons, such as people with eating disorders (such as anorexia or bulimia), often use non-steroidal anti-inflammatory drugs (NSAIDs), alcohol, prolonged hunger, bad eating habits (like skipping meals or eating too much at one sitting), and severe and continuous stress [1]. A stomach ulcer is a kind of benign damage to the mucosa and submucosa of the digestive tract. There is usually a connection between the secretion of stomach acid and this damage. However, the main cause of these ulcers is considered to be the presence and proliferation of *Helicobacter pylori* bacteria, which causes peptic ulcers in various ways, including damage to the protective layer of the stomach mucosa, hence the main treatment is an antibiotic treatment. The prevalence of this disease is 6 to 15% [3, 2].

According to the World Health Institute, 1 out of every 10 people in the US will have a disease called peptic ulcer disease. 15,000 people die from this disease every year. The economic impact of this disease is very large, costing more than 10 billion dollars in the United States each year [4]. Treating ulcers in the stomach with chemicals such as omeprazole (a medicine used to treat heartburn), metronidazole (a medicine used to treat bacterial infections), or ranitidine (a medicine used to treat ulcers in the stomach) is expensive, and can cause some side

*Correspondent author: Pharmaceutical Sciences Research Center, Health Institute, Kermanshah University of Medical Science, Kermanshah, Iran

Email Address: mh.farzaei@gmail.com

effects, and there is a possibility of the recurrence of lesions after stopping the treatment with them, that is why there is a wide effort to find effective compounds [5].

The use of medicinal plant products in the prevention and treatment of diseases has a history as long as human life. Natural and herbal materials are used because of having fewer side effects, unique advantages of good therapeutic efficacy, and they are cheaper than synthetic products [6]. *Plantago major* leaves are used to treat cough and stimulate the mucous membrane in order to deal with the complications of respiratory tract infections. *Plantago* is an Indian name meaning "medicine of life". Studies show that the methanolic extract of *Plantago major* has antibacterial properties against gram-positive and gram-negative bacteria. Also, one of its most important properties is its anti-inflammatory and antibacterial properties, which can treat skin disorders such as inflammation, insect bites, cuts, eczema [7].

Plantago major is a valuable medicinal plant that contains a high level of secondary metabolites. About 60 secondary metabolites have been recognized from the *Plantago major* including phenylethanoid glycosides, polysaccharides, triterpenoids, phenolic acids and other compounds [8-10] such as alkaloids, caffeic acid derivatives, coumarins, polysaccharides, mucilage, fats and oils, sterols and volatile substances. These active secondary metabolites contribute the ulcer healing, decrease gastric secretion, raise gastric pH, and increase mucus secretion with a variety of proposed mechanisms [11, 12].

There are several studies on the anti-ulcerative effects of *Plantago major* but none of them examined the anti-ulcerative effect of the aqueous and hydroalcoholic extracts of *Plantago major* leaves on ethanol-induced gastric ulcer [13, 14]. Therefore, the goal of this study is to investigate the protective effect of the aqueous and hydroalcoholic extracts of *Plantago major* leaves on gastric ulcer induced by ethanol in rats.

METHOD AND MATERIALS

Preparation of the *Plantago Major* Plant

In the present study, *Plantago major* leaves, are collected from Kermanshah province, west of Iran. The herbarium specimen was identified by Dr. Jalilian, Herbarium of Research Center of Agriculture and Natural Resources of Kermanshah province, Kermanshah, Iran; and it is kept in the herbarium of Research Center of Agriculture College with the voucher number 10394. The plant was thoroughly washed and the soil on its surface was cleaned well. Its leaves are separate and exposed to air flow at room temperature and in the shade until drying. Finally, the isolated leaves were finely chopped in suitable sizes for extracting.

Extract Preparation

In order to prepare the extract from the leaves of the *Plantago major*, the dried plant was ground and for hydroalcoholic extraction, 100 grams of the plant was weighed and transferred to a glass percolator, and the extraction was carried out using the solvent of water and ethanol (1000 cc) in the ratio of 70:30. To prepare the aqueous extract, 100 grams of the plant was weighed and distilled water (1000 cc) was added to it. Each of the extracts was poured separately into a 2000 ml Erlenmeyer flask and then left in a shaker for 3 days. Next, the extracted extract was filtered and transferred to a rotary device and concentrated at room temperature under vacuum and then transferred to the crystallizer and kept under the hood until completely dry [15].

Assessment of Total Phenolic and Flavonoid Content of *Plantago Major* in Ethanolic Extract

The total phenolic content of the extracts was determined using the Folin and Ciocalteu reagent. Samples and standards were measured at 765 nm using a spectrophotometer (Cary 50 Bio UV-Vis Spectrophotometer, Varian) and compared to reagent blanks. Folin-Phenol Ciocalteus Reagent (0.2 mL) was added to the test sample (0.2 mL) with 0.6 mL water (1:1). 1 mL of saturated sodium carbonate solution (8% w/v in water) was added, then make up to 3 mL with distilled water after 5 min. After 30 minutes of storage in the dark, the reaction was centrifuged and the blue absorbance of the samples was measured at 765 nm. Total phenol content was calculated using a formula derived from a standard gallic acid calibration curve [16].

The total amount of flavonoids in the samples was determined using the aluminum chloride colorimetric method. Quercetin was used to generate a standard calibration curve for measuring total flavonoid concentrations. A quercetin stock solution was prepared by solubilizing 5.0 mg of quercetin in 1.0 ml of methanol, and a standard

solution of quercetin was prepared by serial dilution using methanol (5-200 µg/ml). Additionally, 0.6 ml of 2% aluminum chloride was combined with 0.6 ml of diluted quercetin standard solution or extract. The mixture was incubated at room temperature for 60 minutes. The absorbance of the reaction solution was evaluated at 420 nm against a blank using a Varian UV-Vis spectrophotometer (Cary 50 Bio UV-Vis spectrophotometer, Varian). Total concentrations of flavonoid content were determined using a standard calibration curve and 3 replicates of each determination were made [16].

Ferric Reducing Antioxidant Potential (FRAP) Assay

The FRAP test was used to assess the ferric-reducing capacity of plant extracts [17]. Antioxidants are compounds that inhibit oxidation, a chemical reaction that can produce free radicals and chain reactions that may damage the cells of organisms. Antioxidants such as thiols or ascorbic acid (vitamin C) may act to inhibit these reactions. To balance oxidative stress, plants and animals maintain complex systems of overlapping antioxidants, such as glutathione. Measurement of the total non-enzymatic antioxidant capacity (TAC) of biological samples is indicative of their ability to counteract oxidative stress-induced damage in cells. TAC is used to provide insights into the development and treatment of oxidative-stress related disorders. In the Total Antioxidant Capacity Assay Kit, either the concentration of the combination of both small molecule and protein antioxidants, or the concentration of only small molecule antioxidants can be determined.

Under acidic condition, Fe^{3+} -TPTZ is converted to Fe^{2+} -TPTZ by both small molecules and proteins. The reduced Fe^{2+} ion chelates with a colorimetric probe, giving a broad absorbance peak at 593nm, which is proportional to the total antioxidant capacity. Because of acidic conditions, and the total plasma concentration of iron ion and ferrous ion in serum samples is usually lower than 10 µM, some endogenous interference factors can be inhibited [18].

Animals and Grouping

In this research, 36 adults male Wistar rats (weight 210 to 270 grams) were purchased from the breeding colony of Kermanshah University of Medical Sciences, and they were kept under standard conditions including room temperature of 24 ± 2 °C and 12 h light/dark cycle and were fed ad libitum for 7 days before the experiment. This study was carried out based on the instructions of the National Institute of Health regarding the care and use of laboratory animals approved by the animal care and use Committee of Kermanshah University of Medical Sciences (IR.KUMS.REC.1400.533).

In order to perform animal studies in the present study, 9 groups (each consist of 4 rats) were used. The mentioned groups are as follows:

- Healthy or normal group
- Famotidine group (receiver of standard drug famotidine with a dose of 20 mg/kg)
- Control group (receiver of ethanol)
- Protective groups that aqueous plant extracts in doses of 50, 100 and 200 mg/kg orally (in the form of gavage) was given to them.
- Protective groups that hydroalcoholic plant extracts in doses of 50, 100 and 200 mg/kg orally (in the form of gavage) was given to them.

In the protective groups, plant extract and standard drug (famotidine) were prescribed for the control group for one week before peptic ulcer induction. At the end, the rats were anesthetized with ketamine (90 mg/kg), and xylazine (10 mg/kg), and after separating the stomach tissue, macroscopic and microscopic examinations were performed [19].

Peptic Ulcer Induction

In the present study, gastric ulcer was induced using the method of oral administration of 1 ml absolute ethanol in the studied groups (rats). Rats were fasted for the duration of 24 hours. Next, for induction of peptic ulcer absolute alcohol was administered orally by gavage. Different protective groups, for the duration of 3 days before and 3 days after peptic ulcer induction, were administered with aqueous and hydroalcoholic leaves extract of *Plantago major* plant via gavage in different doses.

After the end of the study period, finally, the stomach was separated and the mucous tissue was examined, and according to the mentioned method, the wound coefficient and the intensity of inflammation and lesion were measured. For this purpose, to measure macroscopic parameters of gastric ulcer (ulcer index), immediately after killing the animals and removing the stomach tissue, washing with normal saline was done and the measurement was continued. It should be noted that in order to eliminate the effect of circadian rhythms, daily gavage and wound induction with ethanol were done at a specific time. Animals transferred to the laboratory an hour before Wound induction, to adapt to the environment [20, 21] .

Macroscopic Evaluations

In the present study, gastric ulcer was measured under a dissecting microscope to perform macroscopic analysis. Gastric ulcer grading by ascoring system was done as described in Table [22].

Table 1 Scoring index in macroscopic evaluation

Row	Desired scoring	The length of the observed lesion
1	1	1 mm
2	2	1-2 mm
3	3	2-4 mm
4	4	4-6 mm
5	5	6 mm

Microscopic Evaluations

In order to carry out microscopic evaluations in the studied groups in this research, tissue pieces were separated that were previously in formalin 10% is fixed, it was embedded in paraffin and studied by histologist using hematoxylinand eosin stain method (H&E stain). In the following and after preparing the slides in the studied groups, the specializedindicators were interpreted by the histopathologist, and the results were reported [23].

Statistical Analysis

In this study, after preparing and checking the obtained results, quantitative data was evaluated with one-way analysis of variance and Tukey's post hoc test using SPSS software. It should be noted that the desired level of significance was ($p < 0.05$).

RESULTS

Total Phenolic and Total Flavonoid Content

Measurement of total phenolic and total flavonoid content was performed by using the kit of Navand lab kit company. Total phenol and flavonoid contents were calculated by using calibration curve (Figure 1 and 2 respectively), the phenolic content was calculated as 318.8 mg/L (OD=0.64) for the hydroalcoholic extract; and the phenolic content was calculated as 94.6 mg/L (OD= 0.21) for the aqueous extract. The flavonoid content was calculated as 202.48 mg/L (OD=0.33) for the hydroalcoholic extract: and the flavonoid content was calculated as 36.39 mg/L (OD=0.59) for the aqueous extract.

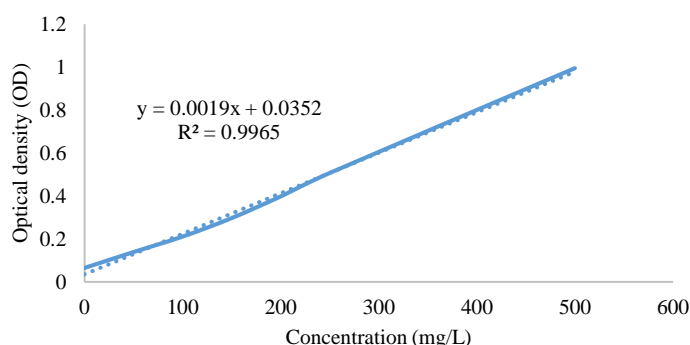


Fig. 1 Standard calibration curve for the determination of total Phenolic Content

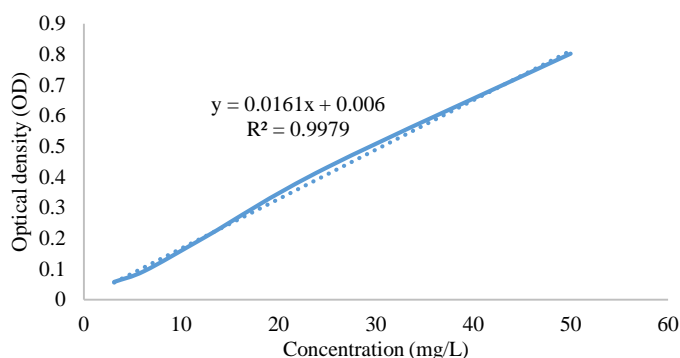


Fig. 2 Standard calibration curve for the determination of total flavonoid content

FRAP Analysis

Measurement of TAC was performed by using FRAP method using the kit of Navand lab kit company. The FRAP assay was used to calculate the ferric reduction power of *Plantago major* extract. Based on the calibration curve, 4.97 mmol Fe²⁺/L (OD=0.39) of FeSO₄.7H₂O was the determined concentration for hydroalcoholic extract; and 0.59 mmol Fe²⁺/L (OD=0.28) was the determined concentration for aqueous extract.

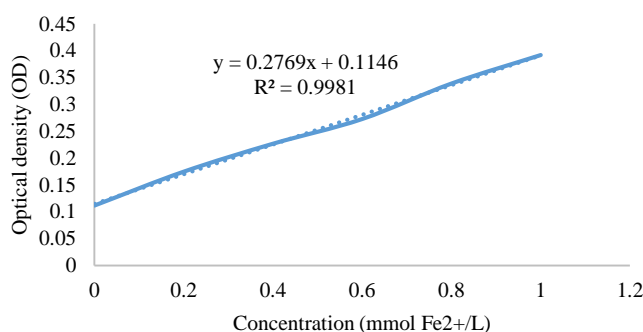


Fig. 3 Standard calibration curve for the determination of FRAP.

Macroscopic Evaluation

The results obtained from the macroscopic examinations showed that in both groups receiving aqueous and hydroalcoholic extracts of the *Plantago major*, the group receiving the extract with a dose of 200 mg/kg had the best protective effect in comparison with the control group, and this difference is statistically significant ($p < 0.05$). In addition, it was shown that the aqueous extract of *Plantago major* plant in doses of 50 and 100 mg/kg also has protective effects, but its amount is less compared to the dose of 200 mg/kg, although statistically in comparison with the control group, there is a significant difference ($p < 0.05$). In addition, in the group receiving hydroalcoholic extract with a dose of 50 and 100 mg/kg, protective effects were also observed, and in the group receiving hydroalcoholic extract with a dose of 50, the observed effect is statistically significant. The obtained results are shown in figures 4, 5, and 6.

Table 2 Histopathological results of the studied groups.

Row	The name of the groups studied	Observed items
1	Control group (ethanol recipient)	Severe submucosa edema with infiltration of necrotic inflammatory cells and tearing of the surface glandular epithelium with congested hyperemia and infiltration of inflammatory cells into the lower layer
2	Famotidine recipient group	Decreased population of gastric gland necrosis, lack of hyperemia and edema, relatively normal submucosa-mucosa.
3	Aqueous extract 100 mg/kg	Decreased population of gastric gland necrosis-mild mucosal hyperemia
4	Aqueous extract 200 mg/kg	Degeneration and mild necrosis, scattered gastric gland cells - mild submucosa hyperemia, infiltration of inflammatory cells and mild edema

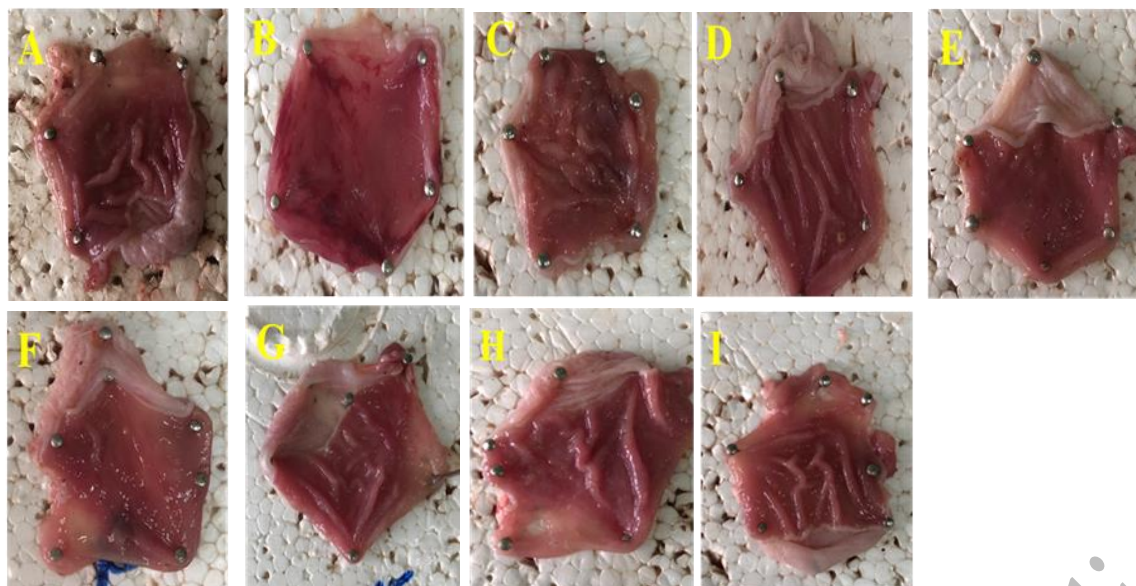


Fig. 4 Images of macroscopic examinations in the studied groups. The images shown in order include A: healthy stomach tissue B: control group (ethanol recipient)-C: famotidine recipient group-D: hydroalcoholic extract 50 mg/kg-E: hydroalcoholic extract 100 mg/kg-F: hydroalcoholic extract 200 mg/kg- G: aqueous extract 50 mg/kg, H: aqueous extract 100 mg/kg, I: aqueous extract 200 mg/kg

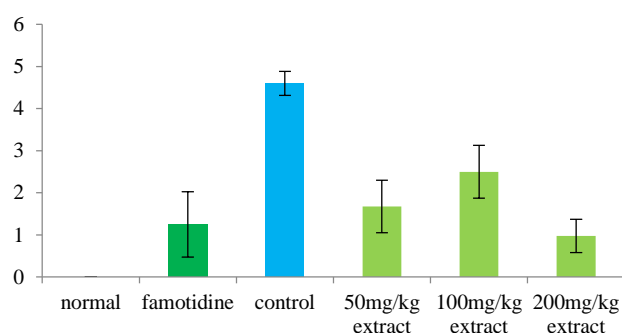


Fig. 5 Macroscopic investigations in the group receiving aqueous extract. The results are presented with $P < 0.05$. #: comparison with famotidine group. *: Comparison with the control group.

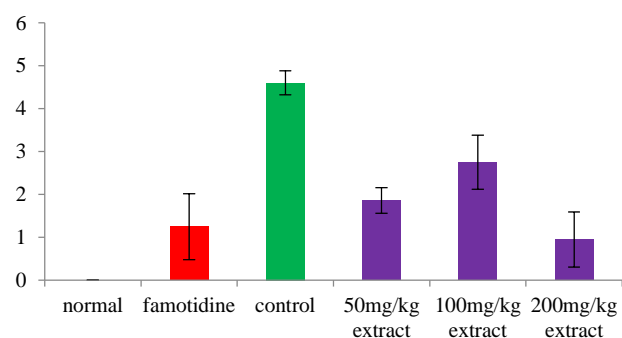


Fig. 6 Macroscopic investigations in the group receiving hydroalcoholic extract. The results are presented with $P < 0.05$. #: comparison with famotidine group. *: Comparison with the control group.

The results obtained from the histopathological studies in this research are shown in Table 2 and Figure 7.

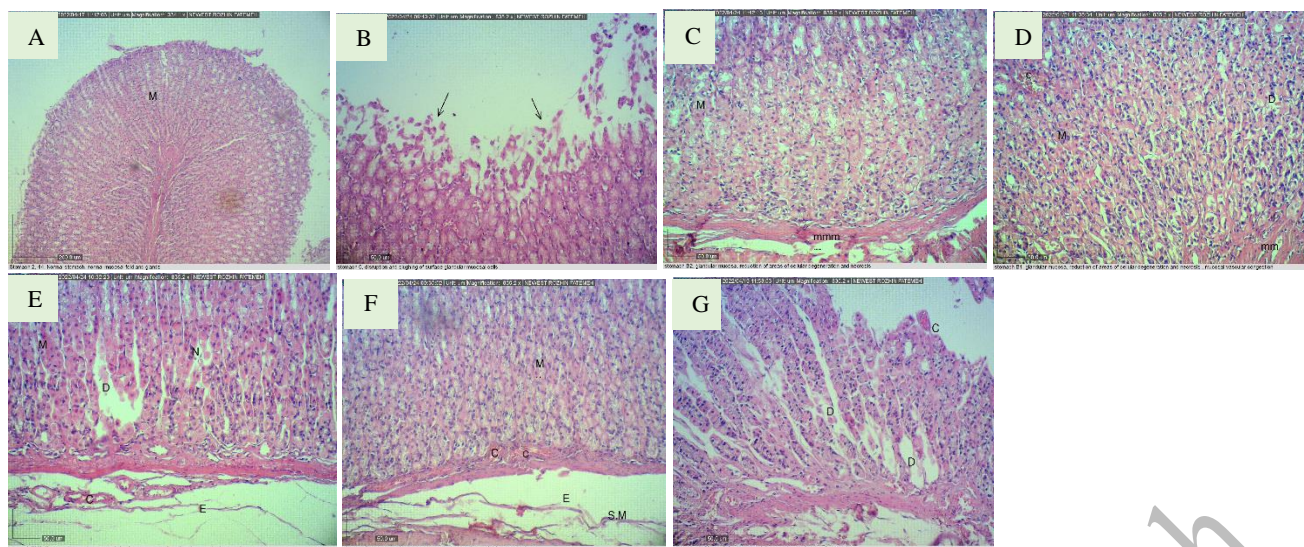


Fig. 7 Histopathological images in the studied groups. The images shown in order include A: healthy stomach tissue B: control group (ethanol recipient) C: Famotidine recipient group D: aqueous extract 100 mg/kg E: aqueous extract 200 mg/kg F: hydroalcoholic extract 100 mg/kg G: hydro alcoholic extract 200 mg/kg.

DISCUSSION

Ulcers in the stomach and intestine are very common. They are caused by many different things, but we don't know exactly what causes them. It has been found that peptic ulcer (PU: a disease in which the balance between offensive and defensive factors is disturbed) is a disease that affects the body's ability to fight off infections [24]. Chronic gastritis (a type of stomach ulcer) penetrates into the muscle and the tissue that lines the stomach. It causes changes in appetite and nausea. It can cause weight loss, indigestion, vomiting and chest pain. Stomach ulcers can cause bleeding, perforation (a hole), pyloric stenosis (a narrowing of the pylorus, the opening between the stomach and small intestine), and cancer [24, 25].

For thousands of years, herbal medicines have been used to treat human stomach ulcers. Various controlled clinical studies have shown that herbal medicines are effective in the treatment of gastric ulcers in humans [26, 27]. The effectiveness of herbal medicines (medicines made from plants) to treat stomach ulcers is similar to that of a drug called famotidine (a drug that blocks the action of acid in the stomach), a histamine H2 receptor antagonist. A study showed that oral herbal medicines for 4 weeks were more effective than cimetidine in the treatment of gastric and duodenal ulcers as well as gastritis [28]. In addition, the combination of herbs and a drug called ranitidine (Zantac) was more effective at treating stomach ulcers than either herb or ranitidine alone [29, 30].

Plantago major (a plant, also known as broad-leaved plantain) is used in traditional medicine to treat wounds, infections of the skin, infections of the respiratory organs (lungs and airways), and digestive organs (stomach and intestines) [31, 32]. For example, circulation, cancer, infection and pain are common [33]. The results of the present study showed that in both groups receiving the aqueous and hydroalcoholic extracts of the leaves of the plant, the group receiving the extract at a dose of 200 mg/kg had the best protective effect in comparison with the control group, and this difference is statistically significant ($p < 0.05$). In addition, it was shown that the aqueous extract of the *Plantago major* plant in doses of 50 and 100 mg/kg also has protective effects, but its amount is lower compared to the dose of 200 mg/kg, although statistically compared to the control group, it has the difference that is significant ($p < 0.05$).

In addition, in the group receiving hydroalcoholic extract with a dose of 50 and 100 mg/kg, protective effects were also observed, and in the group receiving hydroalcoholic extract with a dose of 50, the observed effect is statistically significant. As a result, by increasing the dose of aqueous and hydroalcoholic extract, its therapeutic effect has also increased. In confirmation of these results, in 2019, the effect of aqueous alcoholic extract of *Plantago* on indomethacin-induced gastric ulcer in rats was analyzed by Paseban and colleagues. The results of these researchers indicated that the dose of 200 mg/kg extract in the treatment groups and all doses of the extract in the prevention groups significantly reduced acid secretion. Their macroscopic results also showed that different

doses of the extract in the prevention groups, 200 mg/kg and 800 mg/kg of the extract in the treatment groups caused a significant decrease in the gastric ulcer index. In the end, they expressed their conclusion that the aqueous alcoholic extract of *Plantago* has a protective effect against gastric ulcer caused by indomethacin by reducing gastric acid secretion [34].

These results confirm the results of the present study in relation to increasing the therapeutic properties of *Plantago* plant in a dose-dependent manner. In research conducted by Hussan and colleague in 2016 with the aim of determining the anti-inflammatory properties of *Plantago major* leaf extract on the inflammatory response following acetaminophen (APAP) hepatotoxicity. The results of this study show that the anti-inflammatory activities of methanol, ethanol and water extracts in laboratory conditions were 26.74 ± 1.6 , $21.69 \pm 2.81\%$ and $12.23 \pm 3.15\%$, respectively. ALT and AST levels were significantly greater in APAP groups on day 1, while the levels of enzyme of all groups showed no significant difference on day 7. The treatment of the extract significantly reduced the levels of pro-inflammatory cytokines and significantly increased the activity of 11β -HSD type 1 enzyme. In conclusion, *Plantago major* extract reduces the inflammatory response following APAP-induced liver injury [35].

The outcomes of this study confirm the results of the present study because inflammatory factors increase in peptic ulcer disease, and as a result of the consumption of *Plantago major* plant, ulcers caused by peptic ulcer are reduced, thus reducing the level of inflammatory factors it is possible that in the mentioned study, *Plantago major* had anti-inflammatory properties.

CONCLUSION

The general results of the present study showed that both aqueous and hydroalcoholic extracts of *Plantago major* leaves, showed a better activity in ulcer models compared with the control groups. Also, the anti-ulcerative activity of *Plantago major* appeared to depend on dose levels. Therefore, based on these findings the antiulcer activity along with its safety profile could make this extract a potential agent for treatment of gastric ulcers.

Declaration of Conflicting Interests

The authors declare that there is no conflict of interest.

REFERENCES

1. Chan F.K. Helicobacter pylori, NSAIDs and gastrointestinal haemorrhage. *European J. Gastroenterology and Hepatology*. 2002;14(1):1-3.
2. Ghahramani R., Sadoogh Abbasian A., Shafaei S. Prevalence of celiac disease in patients with different types of dyspepsia. *J. Isfahan Medical School*. 2009;27(93):65-73.
3. Kalantari H., Nourian S.M. Prevalence of Peptic Ulcer Versus Non Ulcer Dyspepsia in Patients which were Admitted for Endoscopy. *J. Isfahan Medical School*. 2011;28(118).
4. Yeomans N.D., Naesdal J. Systematic review: ulcer definition in NSAID ulcer prevention trials. *Alimentary Pharmacology and Therapeutics*. 2008;27(6):465-72.
5. De M., Krishna De A., Banerjee A.B. Antimicrobial screening of some Indian spices. *Phytotherapy Research: An Int. J. Devoted to Pharmacol. and Toxicological Evaluation of Natural Product Derivatives*. 1999;13(7):616-8.
6. Gilani A.H., Jabeen Q., Ghayur M.N., Janbaz K.H., Akhtar M.S. Studies on the antihypertensive, antispasmodic, bronchodilator and hepatoprotective activities of the *Carum copticum* seed extract. *J. Ethnopharmacology*. 2005;98(1-2):127-35.
7. Sharifa A.A., Neoh Y.L., Iswadi M.I., Khairul O., Abdul Halim M., Jamaludin M., Mohamed Azman A.B., Hing H.L. Effects of methanol, ethanol and aqueous extract of *Plantago major* on gram positive bacteria, gram negative bacteria and yeast. *Ann Microsc*. 2008;8:42-4.
8. Wang H., Zhao C., Huang Y., Wang F., Li Y., Chung H.Y. Chemical constituents and bioactivities of plantaginis herba. *Hong Kong Med J*. 2015;22:29-35.
9. Nemereshina O.N., Tinkov A.A., Gritsenko V.A., Nikonorov A.A. Influence of Plantaginaceae species on E. coli K12 growth in vitro: Possible relation to phytochemical properties. *Pharmaceutical Biology*. 2015;53(5):715-24.
10. Gonçalves S., Romano A. The medicinal potential of plants from the genus *Plantago* (Plantaginaceae). *Industrial Crops and Products*. 2016;83:213-26.

11. Akram M., Hamid A., Khalil A., Ghaffar A., Tayyaba N., Saeed A., Ali M., Naveed A. Review on medicinal uses, pharmacological, phytochemistry and immunomodulatory activity of plants. *International J. Immunopathology and Pharmacol.* 2014;27(3):313-9.
12. Kuhn M.A., Winston D. *Herbal therapy and supplements: a scientific and traditional approach.* Lippincott Williams and Wilkins; 2000.
13. Bagheri S.M., Zare-Mohazabieh F., Momeni-Asl H., Yadegari M., Mirjalili A., Anvari M. Antiulcer and hepatoprotective effects of aqueous extract of *Plantago ovata* seed on indomethacin-ulcerated rats. *Biomedical J.* 2018;41(1):41-5.
14. Ragheb E.M., Ibrahim E.S., Shalaby R.A. Potential Protective Effects of *Plantago major* Extracts against Indomethacin-Induced Gastric Ulcer in Rats. *Egyptian J. Nutrition and Health.* 2021;16(1):1-20.
15. Farzaei F., Heydarpour F., Farzaei M.H., Haghighi Z.M., Abbasabadi Z., Sadeghi E. Protective Effect of *Ferulago angulata* (Schltdl.) Boiss. Hydroalcoholic Extract against Acetic Acid-induced Colitis in Rat: Role of Pro-inflammatory Cytokines. *Pharmacognosy Res.* 2018;10(4).
16. Chandra S., Khan S., Avula B., Lata H., Yang M.H., ElSohly M.A., Khan I.A. Assessment of total phenolic and flavonoid content, antioxidant properties, and yield of aeroponically and conventionally grown leafy vegetables and fruit crops: A comparative study. *Evidence-based Complementary and Alternative Medicine.* 2014;2014.
17. Dudonne S., Vitrac X., Coutiere P., Woillez M., Mérillon J.M. Comparative study of antioxidant properties and total phenolic content of 30 plant extracts of industrial interest using DPPH, ABTS, FRAP, SOD, and ORAC assays. *J. Agric and Food Chemistry.* 2009;57(5):1768-74.
18. Benzie I.F., Strain J.J. The ferric reducing ability of plasma (FRAP) as a measure of "antioxidant power": the FRAP assay. *Analytical Biochemistry.* 1996;239(1):70-6.
19. Memariani Z., Sharifzadeh M., Bozorgi M., Hajimahmoodi M., Farzaei M.H., Gholami M., Siavoshi F., Saniee P. Protective effect of essential oil of *Pistacia atlantica* Desf. on peptic ulcer: Role of α -pinene. *J Traditional Chinese Medicine.* 2017;37(1):57-63.
20. Heeba GH., Hassan M.K., Amin R.S. Gastroprotective effect of simvastatin against indomethacin-induced gastric ulcer in rats: role of nitric oxide and prostaglandins. *European J. Pharmacol.* 2009;607(1-3):188-93.
21. Tariq M., Khan H.A., Elfaki I., Arshaduddin M., Al Moutaery M., Al Rayes H., Al Swailam R. Gastric antisecretory and antiulcer effects of simvastatin in rats. *J. Gastroenterology and Hepatology.* 2007;22(12):2316-23.
22. Sumbul S., Ahmad M.A., Mohd A., Mohd A. Role of phenolic compounds in peptic ulcer: An overview. *J. Pharmacy and Bioallied Sci.* 2011;3(3):361.
23. Farzaei M.H., Khazaei M., Abbasabadi Z., Feyzmahdavi M., Mohseni G.R. Protective effect of *tragopogon graminifolius* DC against ethanol induced gastric ulcer. *Iranian Red Crescent Medical J.* 2013;15(9):813.
24. Singh S., Khajuria A., Taneja S.C., Khajuria R.K., Singh J., Johri R.K., Qazi G.N. The gastric ulcer protective effect of boswellic acids, a leukotriene inhibitor from *Boswellia serrata*, in rats. *Phytomedicine.* 2008;15(6-7):408-15.
25. Nabavizadeh F., Alizadeh A.M., Adeli S., Golestan M., Moloudian H., Kamalinejad M. Gastroprotective effects of *Stachys Lavandulifolia* extract on experimental gastric ulcer. *Afr J. Pharm Pharmacol.* 2011;5(2):155-9.
26. He L.Z., Zhang Q., Wang S.C. Clinical study on treatment of gastric ulcer with qingwei zhitong pill. *Zhongguo Zhong xi yi jie he za zhi Zhongguo Zhongxiyi jiehe zazhi= Chinese J. Integrated Traditional and Western Medicine.* 2001;21(6):422-3.
27. Awuchi C.G., Saha P., Amle V.S., Nyarko R.O., Kumar R., Boateng E.A., Kahwa I., Boateng P.O., Asum C. A Study of Various Medicinal Plants used in Ulcer Treatment: A Review. *J. Res in Applied Sci and Biotech.* 2023;2(1):234-46.
28. Wang CH., Wang Y.H., Zhou Y. Clinical and experimental study on effect of Chinese herbal drugs on producing prostaglandin in gastric mucosa. *Zhongguo Zhong xi yi jie he za zhi Zhongguo Zhongxiyi Jiehe Zazhi= Chinese J. Integrated Traditional and Western Medicine.* 1994;14(9):528-30.
29. García-González M.A., Bujanda L., Quintero E., Santolaria S., Benito R., Strunk M., Sopena F., Thomson C., Pérez-Aisa A., Nicolás-Pérez D., Hijona E. Association of PSCA rs2294008 gene variants with poor prognosis and increased susceptibility to gastric cancer and decreased risk of duodenal ulcer disease. *International J. cancer.* 2015;137(6):1362-73.
30. Sostres C., Carrera-Lasfuentes P., Benito R., Roncales P., Arruebo M., Arroyo M.T., Bujanda L., García-Rodríguez L.A., Lanás A. Peptic ulcer bleeding risk. The role of *Helicobacter pylori* infection in NSAID/low-dose aspirin users. *Official J. the American College of Gastroenterology| ACG.* 2015;110(5):684-9.
31. Baghizadeh A., Davati A., Heidarlooe A.J., Emadi F., Aliasl J. Efficacy of *Plantago major* seed in management of ulcerative colitis symptoms: A randomized, placebo controlled, clinical trial. *Complementary Therapies in Clinical Practice.* 2021;44:101444.
32. Albahri G., Badran A., Hijazi A., Daou A., Baydoun E., Nasser M., Merah O. The therapeutic wound healing bioactivities of various medicinal plants. *Life.* 2023;13(2):317.

33. Nazarizadeh A., Mikaili P., Moloudizargari M., Aghajanshakeri S., Javaherypour S. Therapeutic uses and pharmacological properties of *Plantago major* L. and its active constituents. *J. Basic Appl Sci Res.* 2013;3(9):212-21.
34. Paseban M., Mousavi Fayzabadi V., Tayyebi Meibodi N., Yousefi M., Hosseini A., Rakhshandeh H. The effect of hydro-alcoholic extract of *Plantago major* on indomethacin-induced gastric ulcer in rats. *Internal Medicine Today.* 2019;10:25(1):16-21.
35. Hussan F., Mansor A.S., Hassan S.N., Kamaruddin T.N., Tasnim T.N., Budin S.B., Othman F. Anti-inflammatory property of *Plantago major* leaf extract reduces the inflammatory reaction in experimental acetaminophen-induced liver injury. *Evidence-Based Complementary and Alternative Medicine.* 2015;1:2015.

Accepted to Online Publish