



Zataria multiflora Essential oil Prevent Iron Oxide Nanoparticles-induced Liver Toxicity in Rat Model

Hamid Reza Attaran^{1*}, Faezeh Fatemi², Azadeh Rasooli³, Abolfazl Dadkhah⁴, Mohammad Reza Mohammadi Malayeri⁵ and Salome Dini⁶

¹Department of Medicine, Faculty of Medicine, Qom Branch, Islamic Azad University, Qom, Iran

²Materials and Nuclear Fuel Research School, Nuclear Science and Technology Research Institute, Tehran, Iran

³Department of Biochemistry, Faculty of Sciences, Payame Noor University, Tehran, Iran

⁴Department of Medicine, Faculty of Medicine, Qom Branch, Islamic Azad University, Qom, Iran

⁵Department of Pathobiology, Faculty of Veterinary Medicine, Garmsar Branch, Islamic Azad University, Garmsar, Iran

⁶Young Researchers and Elite Club, Karaj Branch, Islamic Azad University, Karaj, Iran

Article History: Received: 22 May 2017 /Accepted in revised form: 29 November 2017

© 2013 Iranian Society of Medicinal Plants. All rights reserve

Abstract

Over loading of iron oxide nanoparticles can causes the liver injury through overproduction of free radicals. *Zataria multiflora* Boiss. (Lamiaceae) has been used for many years in folk medicine due to its antioxidant and antibacterial activities. This study evaluates -for the first time- the effect of *Z. multiflora* essential oil (EO) against iron oxide nanoparticles hepatotoxicity in rat model. Male Wistar rats were divided randomly into 4 groups; control group (C), non-treated control group (NT), treatment groups, nanoparticles plus *Z. multiflora* EO at 100 and 200 mg/kg b.w. In following, the liver and blood tissue were collected for estimating oxidative stress/antioxidant parameters including lipid peroxidation (LP), glutathione (GSH), glutathione-S-transferase (GST), and liver enzyme aspartate transaminase (AST) and also histopathological examinations. Iron oxide nanoparticles toxicity produced a significant increase in the levels of LP, ferric reducing ability of plasma (FRAP), and AST activity concomitant with decrease in the levels of GSH and GST activity compared to the control group. However, in the treatment groups received *Z. multiflora* EO, the levels of LP and AST activity reduced together with increasing in GSH content and GST activity were significantly reported. Histopathological studies also supported the biochemical assessments indicating hepatic improvements induced by nanoparticles. *Z. multiflora* EO protected the liver from injuries induced by iron oxide nanoparticles which can be correlated with its antioxidant activities. This can be a valuable candidate in modulating the oxidative hepatic injuries.

Keywords: Hepatotoxicity, Oxidative stress, Antioxidant parameters, Antioxidant agents

Introduction

A huge mass of biochemical functions and physiological roles of the liver makes it a crucial factor of health and a target in disease. Acute hepatic injury known as the most serious health problem worldwide is mainly caused by exposing to hepatotoxins, xenobiotics, and chemotherapeutic

agents that lead to impairment of its functions [1]. Nanoparticles with very special feature (shape, size, and high proportion of surface to volume) including the elements of cobalt, iron, and nickel can easily enter into bloodstream thorough respiration and digestion systems [2]. Therefore, the liver can be seen as a target organ to identify

*Corresponding author: Department of Medicine, Faculty of Medicine, Qom Branch, Islamic Azad University, Qom, Iran
Email Address: attaranhamidreza@yahoo.com

adverse effects of *in vivo* exposure to iron oxide nanoparticles.

The liver damage due to iron nanoparticles is well-informed [3]. Iron oxide nanoparticles can be used for medical imaging, disease diagnosis, drug delivery, cancer treatment, gene therapy, and other cases. These particles accumulate in the liver cells and lead to oxidative stress with generation of reactive oxygen species (ROS) [3]. The role of iron overloading in the progression of hepatic damage in various clinical and experimental conditions has usually been studied by iron loading [4-6]. Cell culture studies confirm the toxicity of engineered nanoparticles reporting cytotoxicity, decreased cell viability, and the production of proinflammatory agents [7-9]. These cell culture studies indicate that the size and particle composition can dramatically modify toxicity [8-10].

Recently, the hepatoprotective activity of several medicinal plants with fewer side effects has been reported [11,12]. One study [13] demonstrated that silymarin and deferoxamine have a protective effect on iron-induced hepatotoxicity in rats. Silymarin can also inhibit lipid peroxidation (LP) with a significant increase in the cellular antioxidant defense machinery by ameliorating the deleterious effects of free radical reaction and the increase in glutathione (GSH) content [14]. Another study [15] showed that the hepatoprotective and antioxidant properties of aqueous fruit extract of *Embilica officinalis* (Euphorbiaceae).

Zataria multiflora Boiss. (Lamiaceae), commonly called Avishan-e-Shirazi, is native to central and southern parts of Iran [16]. Although, the herb is used as food flavoring, it is diversely utilized in the traditional medicine for its antiseptic, analgesic, antispasmodic, and anti-inflammatory properties [17-19]. Our previous GC and GC/MS analysis of Iranian *Z. multiflora* essential oil (EO) identified the main bioactive compounds which were thymol, carvacrol, p-cymene, and -terpinene. The results also have been informed the direct correlation between those major compositions and high antioxidant and antimicrobial potentials of the essential oil. We also demonstrated that the chemopreventive activity of Iranian *Z. multiflora* EO against DMH-induced colon carcinogenesis through modulatory DMH-metabolizing enzyme activities, i.e. cytochrome P450 (CYP450) and glutathione-S-transferase (GST), concomitant with decreasing levels of -catenin protein level [22].

Other studies also indicated a great range of *Z. multiflora* EO biological activities such as antifungal, anti-inflammatory [18,23-25], and antimicrobial, anti-nociceptive, antierythma, antibacterial [26-35] which could be attributed to the presence of high quantity of carvacrol and thymol as main phenolic compounds and p-cymene as the main non-phenolic compounds [36].

To the best of our knowledge, the protective effect of *Z. multiflora* EO has not reported yet. So, in order to propose an alternative drug which would be used more safely and efficiently in the liver injuries as well as following our recent achievements, in this study, we evaluate the hepatoprotective activity of Iranian *Z. multiflora* EO against iron oxide nanoparticles induced liver toxicity in rat model.

Material and Methods

Preparation of *Z. multiflora* EO

Fresh *Z. multiflora* was collected in May 2010 from the Shiraz City (Latitude: 29°30'N Longitude: 55°00'E), Iran. Dr. Younes Asri (Botanist) authenticated the plant materials from herbarium of Iranian botanical garden (TARI) (Voucher Number: 41754).

EO Extraction

Oil extraction from the aerial parts of *Z. multiflora* was carried out using a Clevenger-type apparatus. The extraction was carried out for 2 h, and the oil was stored in dark glass bottles in a freezer until further use [20].

Synthesis of Iron Oxide Nanoparticles

Alpha- Fe_2O_3 iron oxide nanoparticles were synthesized by co-precipitation method in which $\text{FeCl}_3 \cdot 6\text{H}_2\text{O}$ was used as a precursor and ammonia as precipitant. Morphology, size distribution and zeta potential of the synthesized nanoparticles were characterized by TEM and DLS techniques, respectively. Type of the synthesized nanoparticles was characterized by XDR technique. The size of nanoparticles was 20 nanometers. It should be mentioned that the nanoparticle did not have any charges.

Animal Treatments

Male Wistar rats 3-4 months of age, weighing 100 g were used throughout this study. The animals were obtained from the Pasteur Institute of Iran and maintained in the animal house facilities. They

were maintained on a commercial pellet food and tap water *ad libitum*. The animals were divided into 4 groups (n=5). In control group (C), rats received normal saline (nanoparticles solution) and dimethyl sulfoxide (DMSO) daily for 3 days. In non-treated control group (NT), iron oxide nanoparticles (Fe₂O₃) (200 mg/kg b.w) was i.p injected daily for 3 days. In the treatment groups, iron oxide nanoparticles (200 mg/kg b.w) plus *Z. multiflora* EO at 100 and 200 mg/kg b.w were i.p injected daily for 3 days. At day 4th, rats were anesthetized and the blood was collected by heart puncture. Rats were killed and liver were removed and processed for histological and biochemical assays as described below.

Preparation of Tissue Homogenate and Plasma

The heparinated blood samples were collected at 4th day by heart puncture from all the animals and centrifuged at 3000 g for 10 min to obtain the plasma. Liver samples were immediately transferred to ice-cold containers and homogenized (20%, w/v) in the appropriate buffer using a homogenizer (E.L.M 2500). The homogenates were used to measure the biochemical parameters.

Biochemical Assays

CYP450 protein assay

CYP450 protein level was performed by ELISA on liver preparations according to the procedure described in the kit from Bioassay Technology Laboratory, China.

GST Activity

Liver cytosolic GST activities were measured spectrophotometrically using CDNB as substrate as described by Habig *et al.* (1974) [37]. The specific activity was calculated based on the nmol/min/mg protein in samples which was measured by Bradford assay [38].

GSH Estimation

GSH was estimated in tissue homogenates according to the procedure of Seldak and Lindsay (1968) [39].

LP Estimation

A weighed portion of liver was homogenized in phosphate buffer (100mM, pH 7.0) and used to measure the level of thiobarbituric acid reactive substances (TBARS) as indices for lipid peroxidation. The concentration of TBARS was measured spectrophotometrically using TBA reagent based on the procedure described by Buege and Aust.

Ferric reducing ability of plasma (FRAP) assay

This assay was performed using 2, 4, 6-tripyridin-2-yl-1, 3, 5-triazine (TPTZ) reagent as described by Benzie and Strain (1996) [40]. FRAP level was calculated by plotting a standard curve of absorbance against $\mu\text{mol/L}$ concentration of Fe (II) standard solution.

Determination of Enzymatic Antioxidants

The activities of superoxide dismutase SOD and CAT were estimated in liver homogenate using the commercial kits (BioVision, Inc., USA), following the instructions given by the company.

Liver Function Tests

To confirm the liver function and injury, serum alanine transaminase (ALT), aspartate transaminase (AST), and alkaline phosphatase (ALP) were determined spectrophotometrically according to the procedure described in the kit purchased from the Pars Azmoon, Co, Iran.

Histological Studies

Preparation of tissues and staining

The liver specimens of all animals were fixed in 10% buffered neutral formalin solution. Then, they processed routinely for paraffin embedding and sectioned for hematoxylin and eosin staining and Lillie's method as iron staining.

Lillie's method staining [41]

The sectioned liver tissues were deparaffinized and hydrated to distilled water. For ferric iron accumulation staining, the sections were placed in potassium ferrocyanide solution for 1 h. Then, they were washed well in 1% aqueous glacial acetic acid and rinsed in distilled water. Finally, the sections were dehydrated in 95% alcohol, absolute alcohol and cleared in xylene and mounted. Iron accumulations were visible as dark Prussian blue.

Histopathological scoring In histopathological assessment, nuclear chromatin clumping, iron accumulation and Kupffer cells hyperplasia were the prominent changes. The histopathological changes were graded numerically to be comparable statistically. The histological scoring was performed as described by Eidi *et al.* (2011) [74], as followings: score 0=no visible cell changes, score 1=focal hepatocyte change on less than 25% of the tissue, score 2=focal hepatocyte change on 25-50% of the tissue, score 3=extensive, but focal hepatocyte change, score 4=global hepatocyte change.

Statistical Analysis

Data are presented as means \pm Standard Error of Mean (SEM) of five samples obtained from five animals in each group. The results were subjected to one-way ANOVA followed by Tukey's HSD using SPSS (version 19.0) software. Significant levels were defined as $P < 0.05$. (*) denote significantly different from the respective negative control group ($P < 0.05$). (**) denote significantly different from the respective control group ($P < 0.05$).

Results

The effects of *Z. multiflora* EO on the oxidative stress/antioxidant parameters and metabolizing enzymes in rats treated by iron oxide nanoparticles

The results indicated that LP level (Table 1) increased as evident by significant rise in the level of MDA (Table 1) at 72 h after iron oxide nanoparticles administration ($P < 0.05$). The iron oxide nanoparticles administration also caused the liver GSH depletion at 72 h after the treatment ($P < 0.05$) (Table 1). The LP and GSH levels returned significantly ($P < 0.05$) to the normal levels after using *Z. multiflora* EO compared to the positive group at 72 h (Table 1). Since iron oxide nanoparticles, as a hepatotoxic agent, induced oxidative damage, the levels of liver antioxidant enzymes SOD, CAT and also plasma FRAP were measured (Table 1). There were no significant changes in CAT and SOD activities (Table 1) after 72 h of iron oxide nanoparticles administration. While, the abnormal high level ($P < 0.05$) of FRAP observed in the iron oxide nanoparticle induced

liver toxicity at 72 h after nanoparticles treatment (Table 1). The serums of FRAP, SOD, and CAT levels did not show any remarkable changes after treatment of *Z. multiflora* EO (Table 1). As shown in Table 1, CYP450 protein level did not significantly alter in the liver of all groups. The level of the detoxifying enzyme GST (Table 1) diminished in rats treated with toxicity dose of iron oxide nanoparticles at 72 h ($P < 0.05$). While, the administration of *Z. multiflora* EO at 100 and 200 mg/kg b.w surprisingly elevated the reduction of serum GST activity induced by iron oxide nanoparticles (Table 1).

The effects of *Z. multiflora* EO on the liver enzymes in rats treated by iron oxide nanoparticles

Serum biochemical parameters including AST, ALT, and ALP in all experimental groups were depicted in Table 2. As shown in Table 2, the activity of the serum AST increased markedly ($P < 0.05$) in iron oxide nanoparticles-treated rats at 72 h as compared to the NT group. However, co-administration of rats with *Z. multiflora* EO surprisingly ($P < 0.05$) restored iron oxide nanoparticles induced the elevation of the serum AST level (72 h) towards normal value (Table 2). Also, the ALT and ALP levels did not affect by treating with iron oxide nanoparticles in all groups (Table 2).

Histopathological Assessments

Histopathologic analysis did not show any obvious lesion in the liver of control group. Iron staining did not show any iron accumulation as well (Fig. 1A and Table 3).

Table 1 The effects of *Zataria multiflora* Boiss. EO on the oxidative stress/antioxidant parameters and metabolizing enzymes in the rats treated by iron oxide nanoparticle at 72 h

Groups	LP (n mol/mg protein)	GSH (n mol/mg protein)	FRAP (μ mol/L)	CAT (mU/mg protein)	SOD (mU/mg protein)	CYP450 (pg/mg protein)	GST (n mol/min/mg protein)
C	1.39 \pm 0.17	460.4 \pm 13.03	631.60 \pm 40.37	7.26 \pm 0.35	12.06 \pm 0.75	1722 \pm 91.29	784.4 \pm 47.33
NT	2.53 \pm 0.11*	342.4 \pm 19.2*	436.40 \pm 17.45*	6.63 \pm 0.27	11.79 \pm 0.61	1668 \pm 77.09	509.8 \pm 28.92*
EO 100	1.45 \pm 0.11**	435.25 \pm 28.28**	445.20 \pm 15.10	6.88 \pm 0.37	12.02 \pm 0.78	1670 \pm 60.13	771 \pm 35.29**
EO 200	1.41 \pm 0.15**	459.75 \pm 15.83**	412.25 \pm 22.27	7.19 \pm 0.38	12.11 \pm 0.77	1662.5 \pm 102.01	819 \pm 55.32**

C: control group; NT: non-treated control group; EO: *Zataria multiflora* Boiss.essential oil (100 & 200 mg.kg b.w) treated groups. * $P < 0.05$ is considered significantly between control group (C) and non-treated control group (NT). ** $P < 0.05$ is considered significantly between non-treated control group (NT) and *Z. multiflora* EO treated groups. Data are presented as mean \pm SD.

Table 2 The effects of *Zataria multiflora* Boiss. EO on the liver enzymes in the rats treated by iron oxide nanoparticle at 72 h

Groups	AST (U/L)	ALT (U/L)	ALP (U/L)
C	112±7.26	37.80±2.63	360±20.24
NT	125.60±8.38*	39.40±3.55	384±22.04
EO 100	121.20±8.86**	36.25±2.05	363.7±23.57
EO 200	113.5±7.68**	34±1.95	366.2±19.08

C: control group; NT: non-treated control group; EO: *Zataria multiflora* Boiss. essential oil (100 & 200 mg/kg b.w) treated groups. *P<0.05 is considered significantly between control group (C) and non-treated control group (NT). **P<0.05 is considered significantly between non-treated control group (NT) and *Z. multiflora* EO treated groups. Data are presented as mean ± SD.

Table 3 Analysis of liver histopathological changes in different study groups

Groups	C	NT	EO (100 mg/kg b.w)	EO (200 mg/kg b.w)
Iron accumulation	0±0	4±0*	2.6±0.5	1.3±0.5**
Chromatin clumping	0±0	3±0*	0.3±0.5**	0.3±0.5**
Kupffer cells Hyperplasia	0±0	3.3±0.5*	2.6±0.5	1.3±0.5**

C: control group; NT: non-treated control group; EO: *Zataria multiflora* Boiss. essential oil (100 & 200 mg/kg b.w) treated groups. *P<0.05 is considered significantly between control group (C) and non-treated control group (NT). **P<0.05 is considered significantly between non-treated control group (NT) and *Z. multiflora* EO treated groups. Data are presented as mean ± SD.

On the other hand, iron oxide nanoparticles significantly accumulated in the periportal hepatocytes and phagocytic cells (Kupffer cells) in the liver of NT group due to nanoparticles injection in comparison with control group (P<0.05).

Increased number of phagocytic cells, clumping of nuclear chromatin and apoptosis of hepatocytes were observed in the periportal region of nanoparticles treated group (NT Group) (Fig. 1B and Table 3). *Z. multiflora* EO administration reduced iron accumulation and the number of Kupffer cells in the liver. However, 200 mg/kg b.w EO administration was more efficient (P<0.05) in comparison with NT group (Fig. 1D and Table 3).

Discussion

Recently, there is a great demand to find a suitable hepatoprotective agent among the natural products especially medicinal plants against toxic chemicals and drugs induced liver injuries. So, the present study was designed to estimate the potential of *Z. multiflora* EO in restoration the equilibrium of the

oxidative stress/antioxidant system in the liver of rats treated with iron oxide nanoparticles.

The nanoparticles rapidly enter circulation and may migrate to the liver, kidney, spleen, lungs, and brain [42-44]. Although the mechanism which nanoparticles cause toxicity in the liver is still uncertain, one of the most probably mechanisms of toxicity was previously pointed the generation of free radical products especially reactive ROS [44]. ROS like hydroxyl radical (HO[•]), hydrogen peroxide (H₂O₂), and superoxide anion (O²⁻) is responsible for stimulating a variety of cellular and physiological actions such as inflammation, apoptosis, and deoxyribonucleic acid (DNA) damage [45-46]. Indeed, ROS has been known to produce cellular and tissue injury through covalent bindings such as DNA strand breaking, increase of LP, and augment fibrosis [3,47,48]. Several studies also suggested that iron oxide nanoparticles were found to significantly reduce the levels of cellular antioxidants led to the oxidative damages of intracellular proteins and DNA and increased LP levels [49,50].

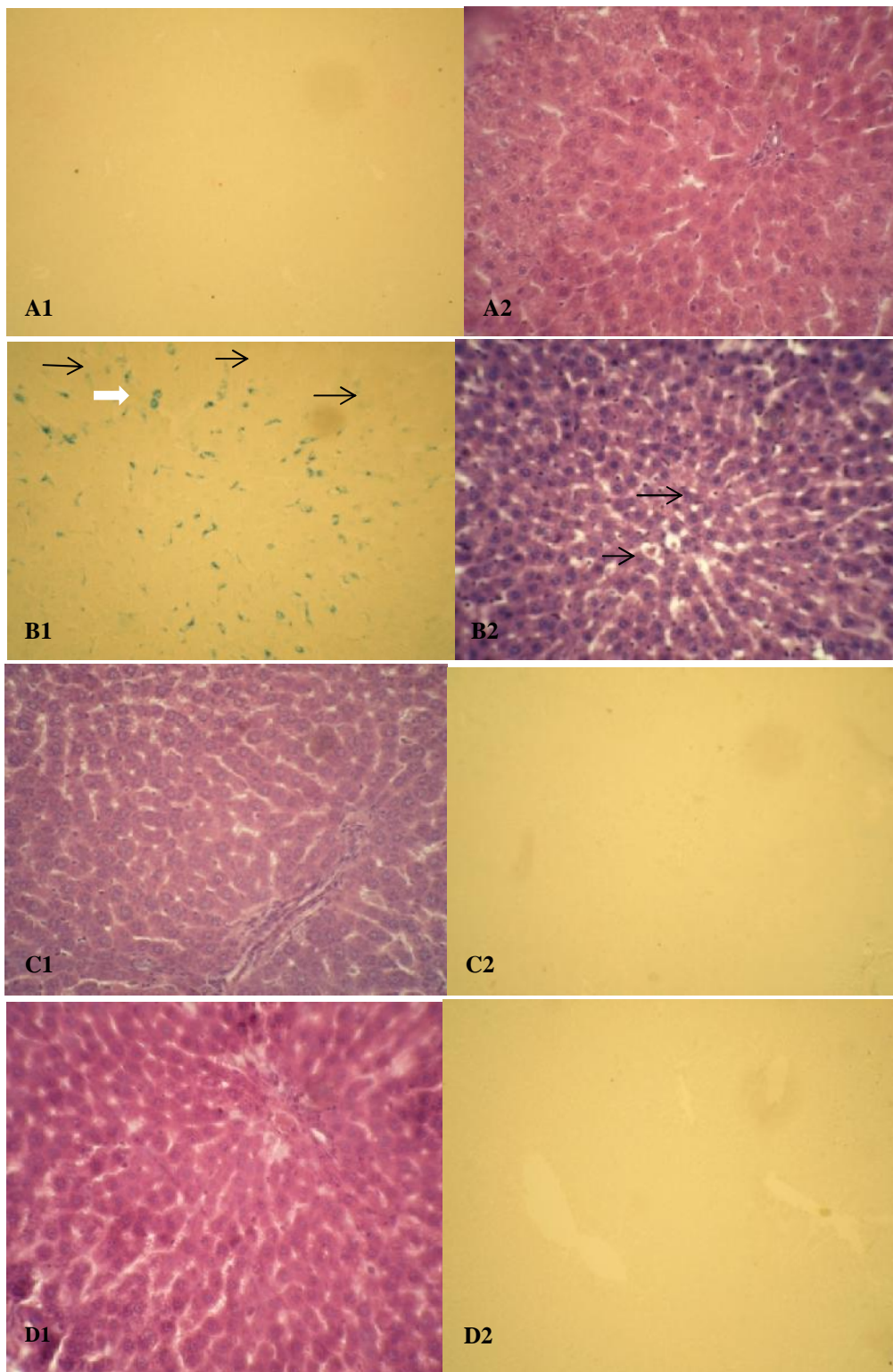


Fig. 1 Effect of *Zataria multiflora* Boiss. EO on histopathological changes 72 h after iron nanoparticles administration. A: control group, A1; liver in control group were completely normal, H&E 400*. A2; there is not any iron accumulation in the liver, Lillie's method staining 400*. B: non-treated control group, B1; periportal changes consist of clumped chromatin, increased phagocytic cells as dark small nuclei (small arrows) and apoptosis (large arrows), H&E 400*. B2; blue stain accumulation of iron particles in hepatocytes and Kupffer cells of periportal region (arrows), Lillie's method staining 400*. C: EO treatment group (100 mg/kg b.w), C1; the hepatocytes show the normal condition, H&E 400*. C2; iron accumulation has decreased in liver in compare with iron nanoparticles treated group. Lillie's method staining 400*. D: EO treatment group (200 mg/kg b.w), D1; The liver is in the normal condition, H&E 400*. D2; There is not any obvious iron accumulation, Lillie's method staining 400*.

In addition, other effects of iron oxide nanoparticles include the reduction of GSH liver cells, increase shock, and oxidative reactions in the liver cells [5]. These changes were confirmed in our study by decreasing in the GSH content together with the elevation of LP level after nanoparticles administration as shown in Table 1. Also, the FRAP level decreasing in the NT group indicating it as an important factor in the balance between oxidative stress and antioxidant status (Table 1). Moreover, the level of AST significantly increased ($P < 0.05$) by 200 mg/kg b.w iron oxide nanoparticles consumption as compared to the normal group (Table 2). Many studies have been done on the hepatotoxicity characteristics of nanoparticles showed that these substances has toxic effects on the liver by increasing ALT, AST and ALP activities [52]. Another study [3] indicated that the significant increase in ($P < 0.05$) AST, ALT, and ALP levels in the groups exposed to the over doses of nanoparticles (150 $\mu\text{g}/\text{kg}$) as compared to the normal group. Also, Jensen *et al.* (2003) investigated the relationship between the extent of hepatocellular injury as reflected by serum levels of ALT, AST, and several iron status indices in 39 anti-hepatitis C virus-negative patients with transfusional iron overload owing to acquired anemia. They observed that serum levels of ALT and AST were directly involved in iron toxicity [53].

Our data were supported by our histopathological examinations (Fig. 1B and Table 3) indicating that iron oxide nanoparticles accumulated in the periportal hepatocytes and phagocytic cells in the liver of NT group due to nanoparticles injection. To increase in the number of phagocytic cells, clumping of nuclear chromatin and apoptosis of hepatocytes were observed in the periportal region of nanoparticles treated group (Fig. 1B and Table 3). Hepatic accumulation of iron oxide nanoparticles affects the liver function. Also, stem cells and fibroblast cells were affected with decreasing of mitochondrial activity which leads to the morphological changes. The results of the present study are similar to the previous reports [54-56] revealed that nanoparticles such as iron oxide nanoparticles can enter into the cells and accumulated in the mitochondria, vesicles, phagosomes, and lysosomes [57-59].

Currently, there have been numerous reports in the hepatoprotective effect of the several medicinal plants [11,60]. As the variable side effects of

modern medicine, the demand for herbal drugs as safe and effective substances for treating injuries is getting more attentions [61]. The phytochemicals derived from plants possess multiple activities. It has been found that natural formulated compound is more active than the isolated form [62]. We previously reported that several medicinal plants with their antioxidant properties could protect the liver against deleterious effects of hepatotoxic agents in rat models [21,63-67]. Moreover, we observed that *Z. multiflora* EO containing high percent of thymol and carvacrol had noticeable chemopreventive, antioxidant, and antimicrobial properties in *in vivo* and *in vitro* systems [20, 64]. In followings, in this study, we demonstrated that *Z. multiflora* EO inhibit nanoparticles induced liver injuries as demonstrated by restoring the levels of LP (Table 1), GST (Table 1), and serum AST (Table 2). Also, the administration of *Z. multiflora* EO mediated ($P < 0.05$) the reduction of GSH content induced by nanoparticles (Table 1). The histopathological findings (Figs. 1C, 1D and Table 3) confirmed that *Z. multiflora* EO improved the liver injury through modulating oxidative stress/antioxidant parameters. In other words, the antioxidant activity of *Z. multiflora* EO may be responsible for protecting the liver from toxicity. *Z. multiflora* EO with the major antioxidant components as thymol, carvacrol, p-cymene, and α -terpinene may enhance the innate mechanisms of the antioxidant system or provide its antioxidant capacity. According to the recent reports, the biological activities of *Z. multiflora* are mostly due to its phenolic compounds; particularly thymol and carvacrol [68,69]. One study [68] also pointed that the existence of thymol in EO might contribute to its pharmaceutical effects like anti-inflammatory, antioxidant, and anticholinesterase properties. It is well documented that thymol and carvacrol act on the microbial cell membrane and cause substantial morphological damage, resulting in a change in permeability and the release of cellular contents [70,71]. Previous studies have also shown that some EO owing scavenging free radicals and antioxidant properties possess considerable hepatoprotective activity [72,73].

Conclusion

The hepatoprotective activity of *Z. multiflora* EO against iron oxide nanoparticles induced liver injuries in *in vivo* experiment was confirmed by

modulating the various oxidative stress/antioxidant parameters *e.g.* LP, GSH, and GST as well as liver enzymes like AST. It was also proved by histopathological findings indicating *Z. multiflora* EO modulatory effects in improving oxidative liver injuries.

Declaration of Interest

This research was conducted by the research deputy grant of Qom Branch, Islamic Azad University.

References

- Asha VV, Pushpangadan P. Preliminary evaluation of the antihepatotoxic activity of *Phyllanthus kozhikodanus*, *P. maderaspatensis* and *Solanum indicum*. *Fitoterapia*. 1998;69:255-259.
- Parivar K, Malekvand Fard F, Bayat M, Alavian SM, Motavaf M. Evaluation of iron oxide nanoparticles toxicity on liver cells of BALB/c rats. *Iran Red Crescent Med J*. 2016;18:1-5.
- Yousefi Babadi V, Najafi L, Najafi A, Gholami H, Beigi Zarji ME, Golzadeh J, Amraie E, Shirband A. Evaluation of iron oxide nanoparticles effects on tissue and enzymes of liver in rats. *J Pharm Biomed Sci*. 2012;23:1-5.
- Houglum K, Filip M, Josephl W, Chojkier M. Malondialehyde and 4-hydroxynonenal protein adducts in plasma and liver of rats with iron overloads. *J Clin Invest Inc*. 1990;86:1991-1998.
- Mayers M, Brent G, Prendergast F, Holman R, Kuntz S, Larusso N. Alterations in the structure, physiochemical properties, and pH of hepatocyte lysosomes in experimental iron overload. *J Clin Invest Inc*. 1991;88:1207-1215.
- Peretz G, Link G, Pappo O, Bruck R, Ackerman Z. Effect of hepatic iron concentration reduction on hepatic fibrosis and damage in rats with cholestatic liver disease. *World J Gastroenterol*. 2006;12:240-245.
- Shvedova AA, Castranova V, Kisin ER, Schwegler-Berry D, Murray AR, Gandelsman VZ, Maynard A, Baron P. Exposure to carbon nanotube material, assessment of nanotube cytotoxicity using human keratinocyte cells. *J Toxicol Environ Health A*. 2003;66:1909-1926.
- Sayes CM, Fortner JD, Guo W, Lyon D, Boyd AM, Ausman KD, Tao YJ, Sitharaman B, Wilson LJ, Hughes JB, West JL, Colvin VL. The differential cytotoxicity of water-soluble fullerenes. *Nano Lett*. 2004;4:1881-1887.
- Monteiro-Riviere NA, Nemanich RJ, Inman AO, Wang YY, Riviere JE. Multi-walled carbon nanotube interactions with human epidermal keratinocytes. *Toxicol Lett*. 2005;155:377-384.
- Goodman CM, McCusker CD, Yilmaz T, Rotello VM. Toxicity of gold nanoparticles functionalized with cationic and anionic side chains. *Bioconjug Chem*. 2004;15:897-900.
- Kharpaté S, Vadnerkar G, Jain D, Jain S. Hepatoprotective activity of the ethanol extract of the leaf of *Prosopium acerifolium*. *Indian J Pharm Sci*. 2007;69:850-852.
- Kumar CH, Ramesh A, Kumar JNS, Ishaq BM. A review on hepatoprotective activity of medicinal plants. *Int J Pharm Sci Res*. 2011;2:501-515.
- Abu Ghadeer AR, Ali SE, Osman SA, Abu Bedair FA, Abbady MM, El-Kady MR. Antagonistic role of silymarin against cardiotoxicity and impaired antioxidant induced by adriamycin and/or radiation exposure in albino rats. *Pakistan J Biol Sci*. 2001;4:604-607.
- Ramadan L, Roushdy HM, Abu Senna GM, Amin NE, El-Deshw OA. Radioprotective effect of silymarin against radiation induced hepatotoxicity. *Pharmacol Res*. 2002;45:447-452.
- Bhuvanewari R, Chidambaranathan N, Jegatheesan K. Hepatoprotective effect of *Embilica officinalis* and its silver nanoparticles against CCl₄ induced hepatotoxicity in Wistar albino rats. *Dig J Nanomater Bios*. 2014;9:223-235.
- Amin G. Popular medicinal plants of Iran. Tehran, Iran: Deputy Minister of Research Publication, Ministry of Health, Treatment, and Medical Education. 1991.
- Mozaffarian V. A dictionary of Iranian plant names, 2nd end. Farhang Moaser Publication, Tehran. 1998.
- Hosseinzadeh H, Ramezani M, Salmani G. Antinociceptive, anti-inflammatory and acute toxicity effects of *Zataria multiflora* Boiss. extracts in mice and rats. *J Ethnopharmacol*. 2000;73:379-385.
- Ramezani M, Hosseinzadeh H, Samizadeh S. Antinociceptive effects of *Zataria multiflora* Boiss. fractions in mice. *J Ethnopharmacol*. 2005;91:167-170.
- Fatemi F, Asri Y, Rasooli I, Alipoor SHD, Shaterloo M. Chemical composition and antioxidant properties of - irradiated Iranian *Zataria multiflora* extracts. *Pharm Biol*. 2012;50:232-238.
- Fatemi F, Dini S, Dadkhah A, Zolfaghari MR. Considering the antibacterial activity of *Zataria multiflora* Boiss essential oil treated with gamma-irradiation *in vitro* and *in vivo* systems. *Radiat Phys and Chem*. 2015;106:145-150.
- Dadkhah A, fatemi F, Mohammadi Malayeri MR, Rasooli A. Cancer chemopreventive effect of dietary *Zataria multiflora* essential oils. *Turk J Biol*. 2014c;38:1-10.
- Boskabady MH, Gholami Mahtaj L. Lung inflammation changes and oxidative stress induced by cigarette smoke exposure in guinea pigs affected by *Zataria multiflora* and its constituent, carvacrol. *BMC Complement Altern Med*. 2015;15:39-49.
- Ezhumalai M, Ashokkumar N, Pugalendi KV. Combination of carvacrol and rosiglitazone high fat diet induced changes in lipids and inflammatory markers in C57BL/6J mice. *Biochimie*. 2015;110:129-136.

25. El-Sayed EM, Mansour AM, Abdul-Hameed MS. Thymol and carvacrol prevent doxorubicin-induced cardiotoxicity by abrogation of oxidative stress, inflammation, and apoptosis in rats. *J Biochem Mol Toxicol.* 2016;30:37-44.
26. Amin M, Kalantar E, Mohammad-Saeid N, Ahsan B. Antibacterial effect and physicochemical properties of essential oil of *Zataria multiflora* Boiss. *Asian Pac J Trop Med.* 2010;3:439-442.
27. Malekinejad H, Bazargani-Gilani B, Tukmechi A, Ebrahimi H. A cytotoxicity and comparative antibacterial study on the effect of *Zataria multiflora* Boiss, *Trachyspermum coticum* essential oils, and Enrofloxacin on *Aeromonas hydrophila*. *Avicenna J Phytomed.* 2012;2:188-195.
28. Raësi M, Tajik H, Razavi Rohani SM, Tepe B, Kiani H, Khosbakht R, Shirzad Aski SA, Tadrissi H. Inhibitory effect of *Zataria multiflora* Boiss. essential oil, alone and in combination with monolaurin, on *Listeria monocytogenes*. *Vet Res Forum.* 2016;7:7-11.
29. Mahboubi A, Kamalinejad M, Abdul Majid Ayatollahi AM, Babaeian M. Total phenolic content and antibacterial activity of five plants of labiatae against four foodborne and some other bacteria. *Iran J Pharm Res.* 2014;13:559-566.
30. Saei-Dehkordi SS, Tajik H, Moradi M, Khalighi-Sigaroodi F. Chemical composition of essential oils in *Zataria multiflora* Boiss. from different parts of Iran and their radical scavenging and antimicrobial activity. *Food Chem Toxicol.* 2010;48:1562-1567.
31. Amanlou M, Beitollahi JM, Abdollahzadeh S, Tohidast-Ekrad Z. Miconazole gel compared with *Zataria multiflora* Boiss. gel in the treatment of denture stomatitis. *Phytother. Res.* 2006;20:966-969.
32. Sajed H, Sahebkar A, Iranshahi M. *Zataria multiflora* Boiss. (Shirazi thyme) an ancient condiment with modern pharmaceutical uses. *J Ethnopharmacol.* 2013;145:686-98.
33. Hosseinimehr SJ, Mahmoudzadeh A, Ahmadi A, Ashrafi SA, Shafaghathi N, Hedayati N. The radioprotective effect of *Zataria multiflora* against genotoxicity induced by irradiation in human blood lymphocytes. *Cancer Biother Radiopharm.* 2011;26:325-329.
34. Gandomi H, Misaghi A, Basti AA, Bokaei S, Khosravi A, Abbasifar A, Jebelli Javan A. Effect of *Zataria multiflora* Boiss. essential oil on growth and aflatoxin formation by *Aspergillus flavus* in culture media and cheese. *Food Chem Toxicol.* 2009;47:2397-2400.
35. Alizadeh NS, Khoei EM, Fazelimanesh M, Aastaneh A. Antibacterial effects of *Zataria multiflora* Boiss. (Shirazi Avishan extract) on urinary tract *Escherichia coli* infections. *Res J Biol Sci.* 2009;4:891-4.
36. Shariffar F, Moshafi MH, Mansouri SH, Khodashenas M. *In vitro* evaluation of antibacterial and antioxidant activities of the essential oil and methanol extract of endemic *Zataria multiflora* Boiss. *Food Control.* 2007;18:800-805.
37. Habig WH, Pabst MJ, Jakoby WB. Glutathione-S-transferases: the first enzymatic step in mercapturic acid formation. *J Biol Chem.* 1974;25:7130-7139.
38. Bradford MM. A rapid and sensitive method for the quantitation of microgram quantities of protein utilizing the principle of protein-dye binding. *Anal Biochem.* 1976;72:248-54.
39. Seldak J, Lindsay RH. Estimation of total protein bound and non-protein sulfidryl groups in tissue with Elman's reagent. *Anal Biochem.* 1968;25:192-205.
40. Benzie IFF, Strain JJ. The ferric reducing ability of plasma (FRAP) as a measure of antioxidant power: the FRAP assay. *Anal Biochem.* 1996;239:70-76.
41. Lillie RD. *Histopathologic technic and practical histochemistry*, 3rd ed. New York, McGraw-Hill Book Co. 1965.
42. Aillon KL, Xie YM, El-Gendy N, Berkland CJ, Forrest ML. Effects of nanomaterial physicochemical properties on *in vivo* toxicity. *Adv Drug Deliv Rev.* 2009;61:457-466.
43. Singh RP, Ramarao P. Cellular uptake, intracellular trafficking and cytotoxicity of silver nanoparticles. *Toxicol Lett.* 2012;213:249-259.
44. Buzea C, Pacheco II, Robbie K. Nanomaterials and nanoparticles: Sources and toxicity. *Biointerphases.* 2007;2:17-71.
45. Nel A, Xia T, Madler L, Lin N. Toxic potential of materials at the nano level. *Science.* 2006;311:622-627.
46. Asharani PV, Mun GK, Hande MP, Valiyaveetil S. Cytotoxicity and genotoxicity of silver nanoparticles in human cells. *ACS Nano.* 2009;3:279-290.
47. Srinivasan R, Chandrasekar MJN, Nanjan MJ, Suresh B. Antioxidant activity of *Caesalpinia digyna* Root. *J Ethnopharmacol.* 2007;113:284-291.
48. Gao M, Li Y, Yang J. Protective effect of *Pedicularis decora* Franch root extracts on oxidative stress and hepatic injury in alloxan-induced diabetic mice. *J Med Plants Res.* 2011;5:5848-5856.
49. Ahmad A, Rasheed N, Banu N, Palit G. Alterations in monoamine levels and oxidative systems in frontal cortex, striatum, and hippocampus of the rat brain during chronic unpredictable stress. *Stress.* 2010;13:356-365.
50. Wan R, Mo Y, Feng L, Chien S, Tollerud DJ, Zhang Q. DNA damage caused by metal nanoparticles: involvement of oxidative stress and activation of ATM. *Chem Res Toxicol.* 2012;25:1402-1411.
51. Handy RD, Shaw BJ. Toxic effects of nanoparticles and nanomaterials: Implications for public health, risk assessment and the public perception of nanotechnology. *Health Risk Soc.* 2007;9:125-144.
52. Shirband A, Azizian H, Pourtezarani M, Rezvani ME, Anvari M, Esmailidehaj M. Dose-dependent effects of iron oxide nanoparticles on thyroid hormone concentrations in liver enzymes: possible tissue destruction. *GJMR.* 2014;1:28-31.
53. Jensen PD, Jensen FT, Christensen T, Nielsen JL, Ellegaard J. Relationship between hepatocellular injury

- and transfusional iron overload prior to and during iron chelation with desferrioxamine: a study in adult patients with acquired anemias. *Blood*. 2003;101:91-96.
54. Bhattacharya A, Ramanathan M, Ghosal S, Bhattacharya SK. Effect of *Withania samra* glycoethanolides on iron-induced hepatotoxicity in rats. *Phytother Res*. 2000;14:568-570.
 55. Whittaker P, Hines FA, Robl MG, Dunkel VC. Histopathological evaluation of liver, pancreas, spleen, and heart from iron overloaded Sprague-Dawley rats. *Toxicol Pathol*. 1996;24:558-563.
 56. Zhao Y, Li H, Gao Z, Xu H. Effects of dietary baicalin supplementation on iron overload-induced mouse liver oxidative injury. *Europ J Pharmacol*. 2005;509:195-200.
 57. Xia T, Kovoichich M, Brant J, Hotze M, Sempf J, Oberley T, Sioutas C, Yeh JI, Wiesner MR, Nel AE. Comparison of the abilities of ambient and manufactured nanoparticles to induce cellular toxicity according to an oxidative stress paradigm. *Nano Lett*. 2006;6:1794-1807.
 58. Gojova A, Guo B, Kota RS, Rutledge JC, Kennedy IM, Barakat1 AI. Induction of inflammation in vascular endothelial cells by metal oxide nanoparticles: effect of particle composition. *Environ Health Perspect*. 2007;115:403-409.
 59. Kirchner C, Liedl T, Kudera S, Pellegrino T, Javier AM, Gaub HE, Stolze S, Fertig N, Parak WJ. Cytotoxicity of colloidal CdSe and CdSe/ZnS nanoparticles. *Nano Lett*. 2005;5:331-338.
 60. Gamal El-din AM, Mostafa AM, Al-Shabanah OA, Al-Bekairi AM, Nagi MN. Protective effect of arabic gum against acetaminophen-induced hepatotoxicity in mice. *Pharmacol Res*. 2003;48:631-635.
 61. De S, Ravishankar B, Bhavsar GC. Plants with hepatoprotective activity: A review. *Ind Drugs*. 1993;30:355-363.
 62. Khopde SM, Indira Priyadarsini K, Mohan h, Gawandi VB, Satav JG, Yakhmi JV, Banavaliker MM, Biyani MK, Mittal JP. Characterizing the antioxidant activity of amla (*Phyllanthus emblica*) extract. *Curr Sci*. 2001;81:185-190.
 63. Dadkhah A, Fatemi F, Ababzadeh S, Roshanaei K, Alipour M, Sadegh Tabrizi B. Preventive role of Iranian *Achillea wilhelmsii* C. Koch essential oils in acetaminophen ninduced hepatotoxicity. *Bot Stud*. 2014a;55:37-47.
 64. Dadkhah A, Fatemi F, Eslami Farsani M, Roshanaei K, Alipour M, Aligolzadeh H. Hepatoprotective effects of Iranian *Hypericum scabrum* essential oils against oxidative stress induced by acetaminophen in rats. *Braz Arch Biol Technol*. 2014b;57:340-348.
 65. Dadkhah A, Fatemi F, Alipour M, Fatourehchi S, Sadat Parchini F. Regulatory effect of Iranian *Hypericum Scabrum* essential oils on hepatic metabolizing enzymes in rats treated by acetaminophen. *J Essent Oil Bear Pl*. 2015a;18:335-348.
 66. Dadkhah A, Fatemi F, Alipour M, Ghaderi Z, Zolfaghari F, Razdan F. Protective effects of Iranian *Achillea wilhelmsii* essential oil on acetaminophen induced oxidative stress in rat liver. *Pharm Biol*. 2015b;53:220-7.
 67. Fatemi F, Allameh A, Khalafi H, Ashrafihelan J. Hepatoprotective effects of -irradiated caraway essential oils in experimental sepsis. *Appl Radiat Isot*. 2010;68:280-285.
 68. Mahboubi M, Bidgoli FG. Antistaphylococcal activity of *Zataria multiflora* essential oil and its synergy with vancomycin. *Phytomedicine*. 2010;17:548-550.
 69. Majlessi N, Choopani S, Kamalinejad M, Azizi Z. Thymol as a main constituent of *zataria multiflora* boiss: essential oil attenuates amyloid -induced cognitive deficits in a rat model of Alzheimer's disease. *Alzheimers Dementia*. 2011;7:770.
 70. Moosavy MH, Akhondzadeh-Basti A, Misaghi A, Zahraei-Salehi T, Abbasifar R, Ebrahimzadeh H, Mousavi HA, Alipour M, Emami Razavi N, Gandomi H, Noori N. Effect of *Zataria multiflora* Boiss. essential oil and nisin on *Salmonella typhimurium* and *Staphylococcus aureus* in a food model system and on the bacterial cell membranes. *Food Res Int*. 2008;41:1050-1057.
 71. Di Pasqua R, Hoskins N, Betts G, Mauriello G. Changes in membrane fatty acids composition of microbial cells induced by addiction of thymol, carvacrol, limonene, cinnamaldehyde, and eugenol in the growing media. *J Agric Food Chem*. 2006;54:2745-9.
 72. Grespan R, Aguiar RP, Giubilei FN, Fuso RR, Damiao MJ, Silva EL, Graton-Mirkcha J, Hernandez L, Bersani-Amado CA, Cuman RKN. Hepatoprotective effect of pretreatment with *Thymus vulgaris* essential oil in experimental model of acetaminophen-induced injury. *Evidence-Based Comp and Alt Med*. 2014;1-8.
 73. Pinho RJD, Rafael Pazinato Aguiar RP, Ricardo Alexandre Spironello RA, Francielli Mariade Souza Silva-Comar FMDSS, Saulo Euclides Silva-Filho SE, Eurica Mary Nogami EM, Ciomar Aparecida Bersani-Amado CA, Roberto Kenji Nakamura Cuman KNC. Hepatoprotective effect of pretreatment with rosemary and ginger essential oil in experimental model of acetaminophen-induced injury. *BJPR*. 2014;4:2126-2135.
 74. Eidi A, Eidi M, Al-Ebrahim M, Rohani AH, Mortazavi P. Protective effects of sodium molybdate on carbon tetrachloride-induced hepatotoxicity in rats. *J Trace Elem Med Biol*. 2011;25:67-71.